
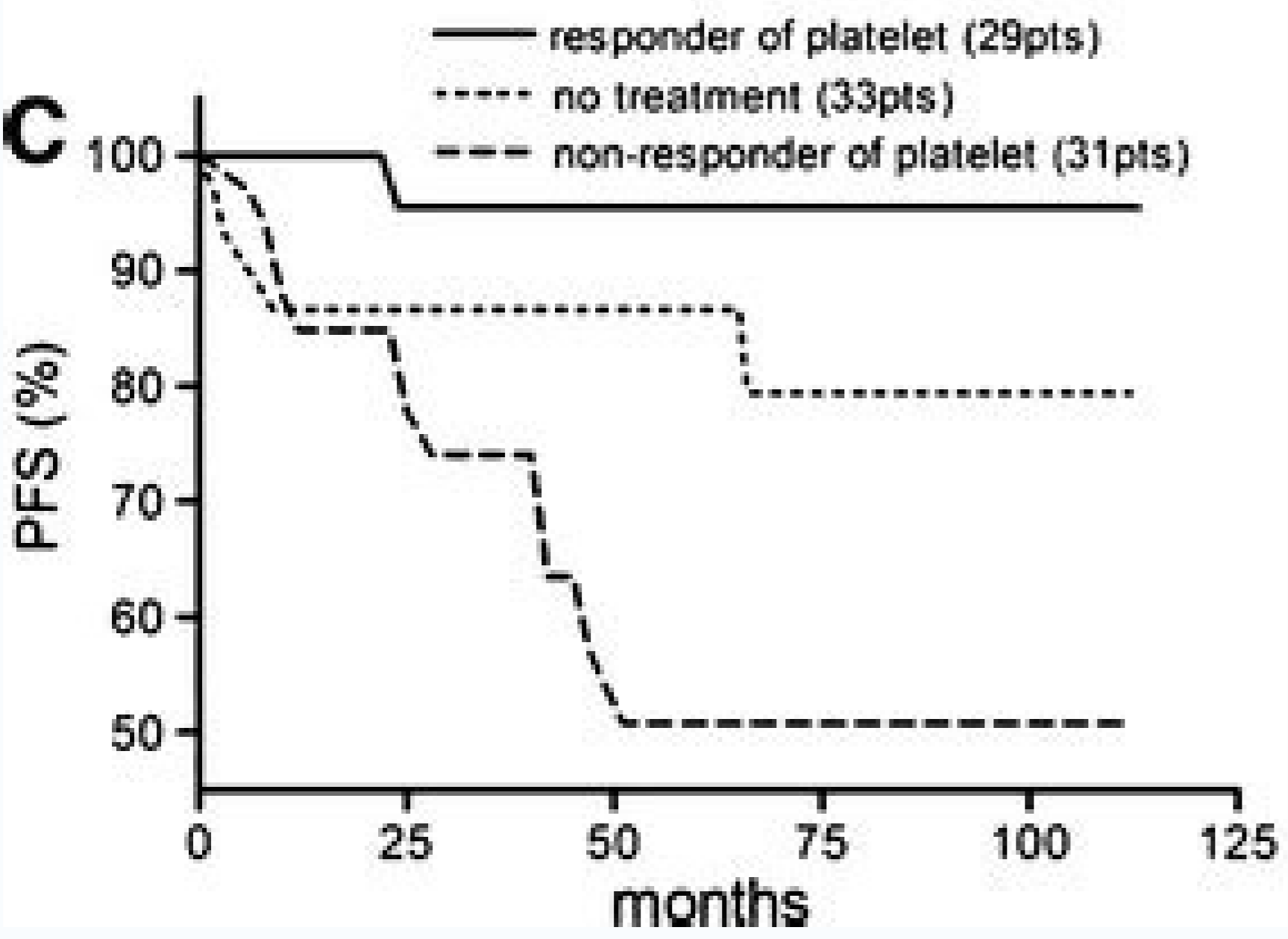
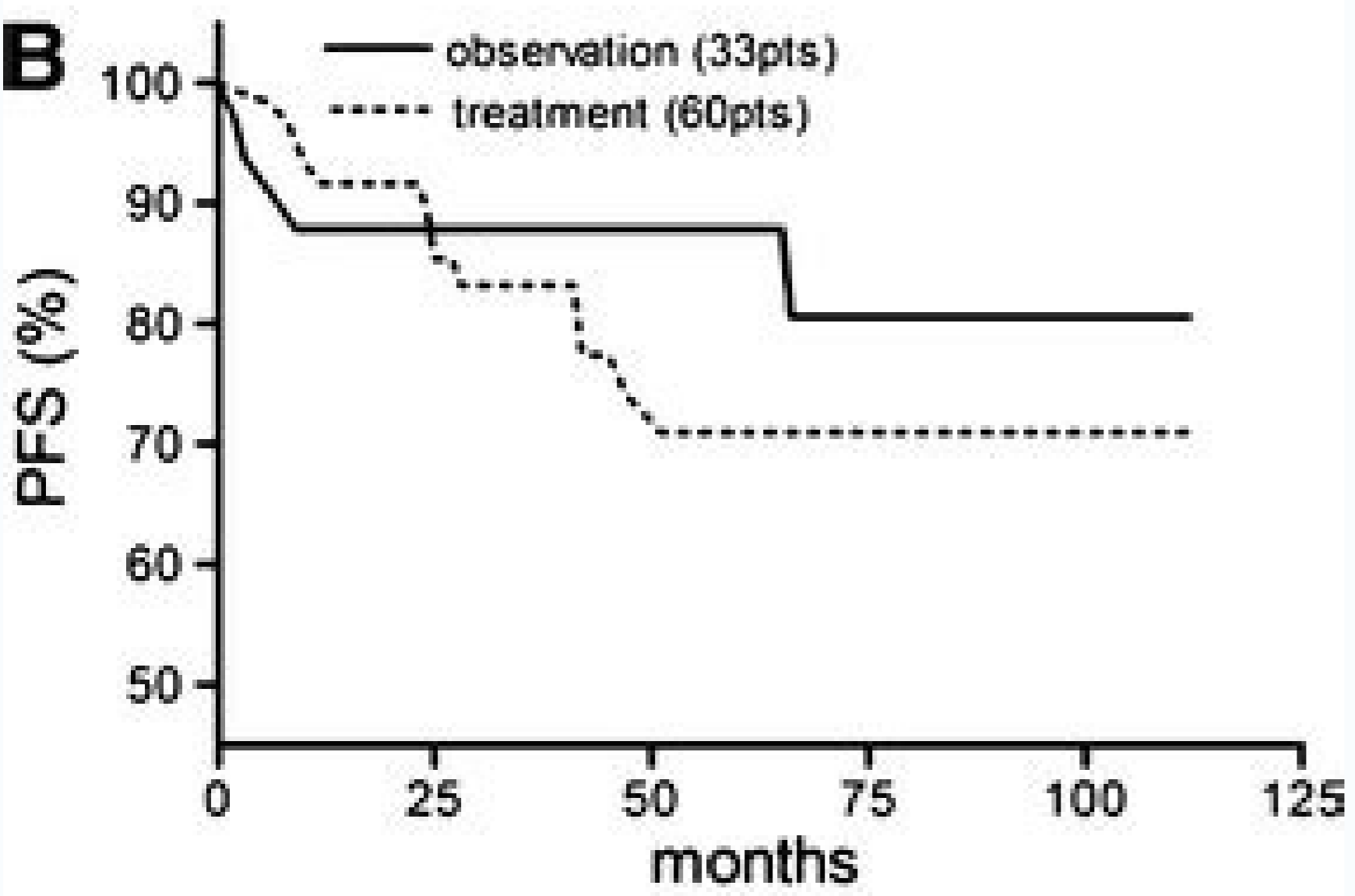
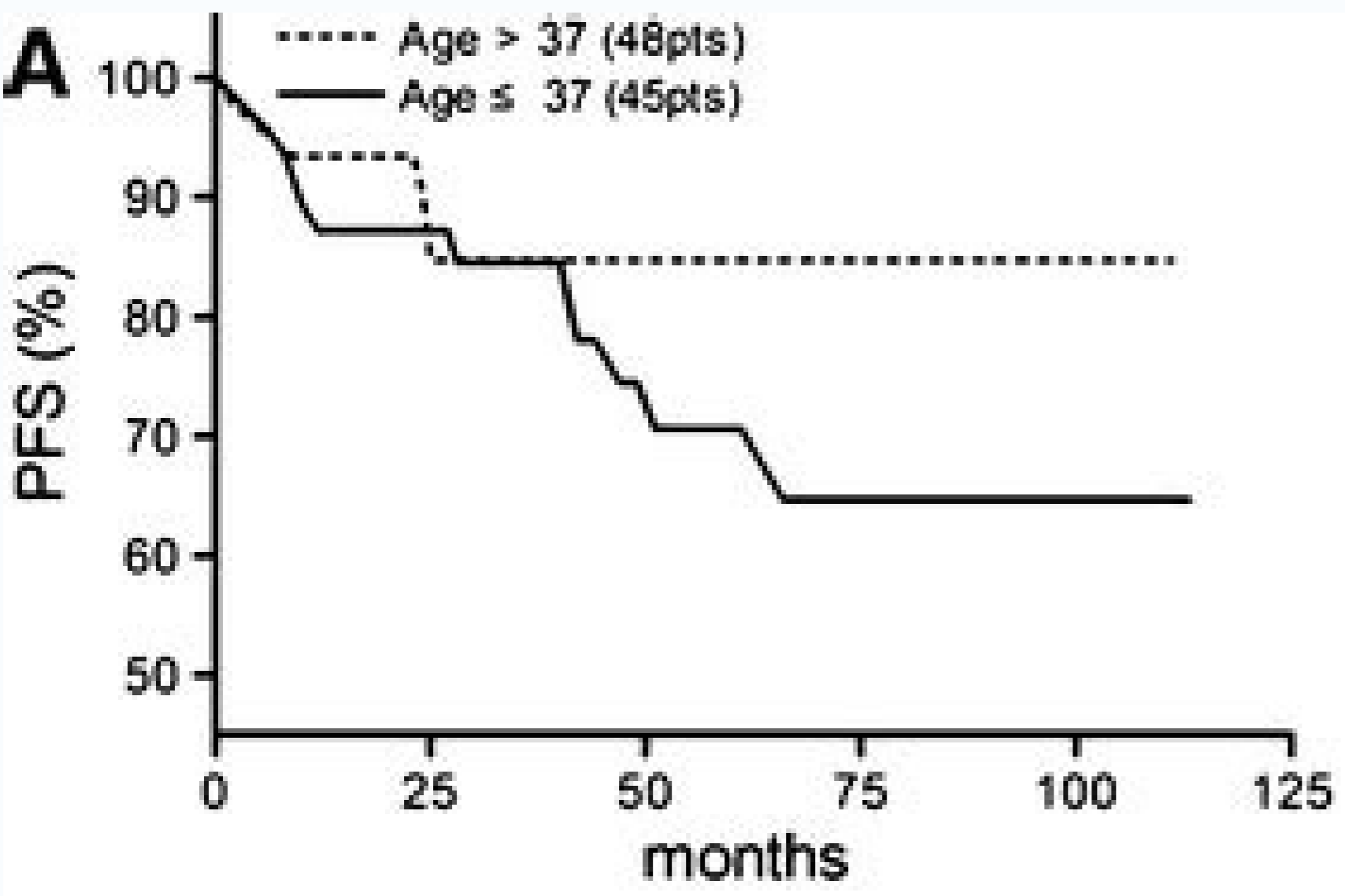
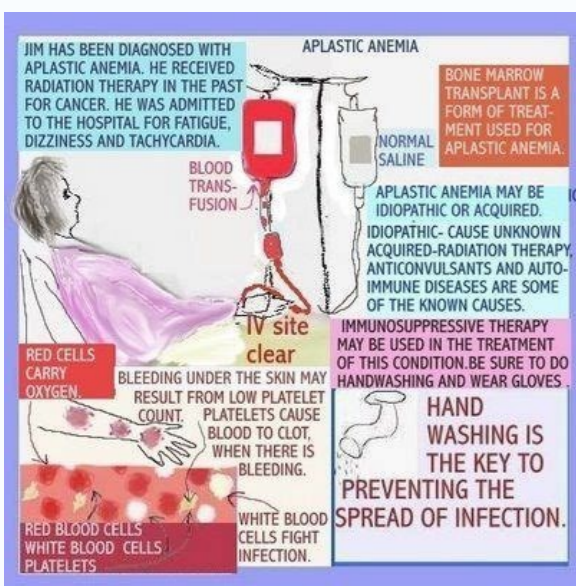

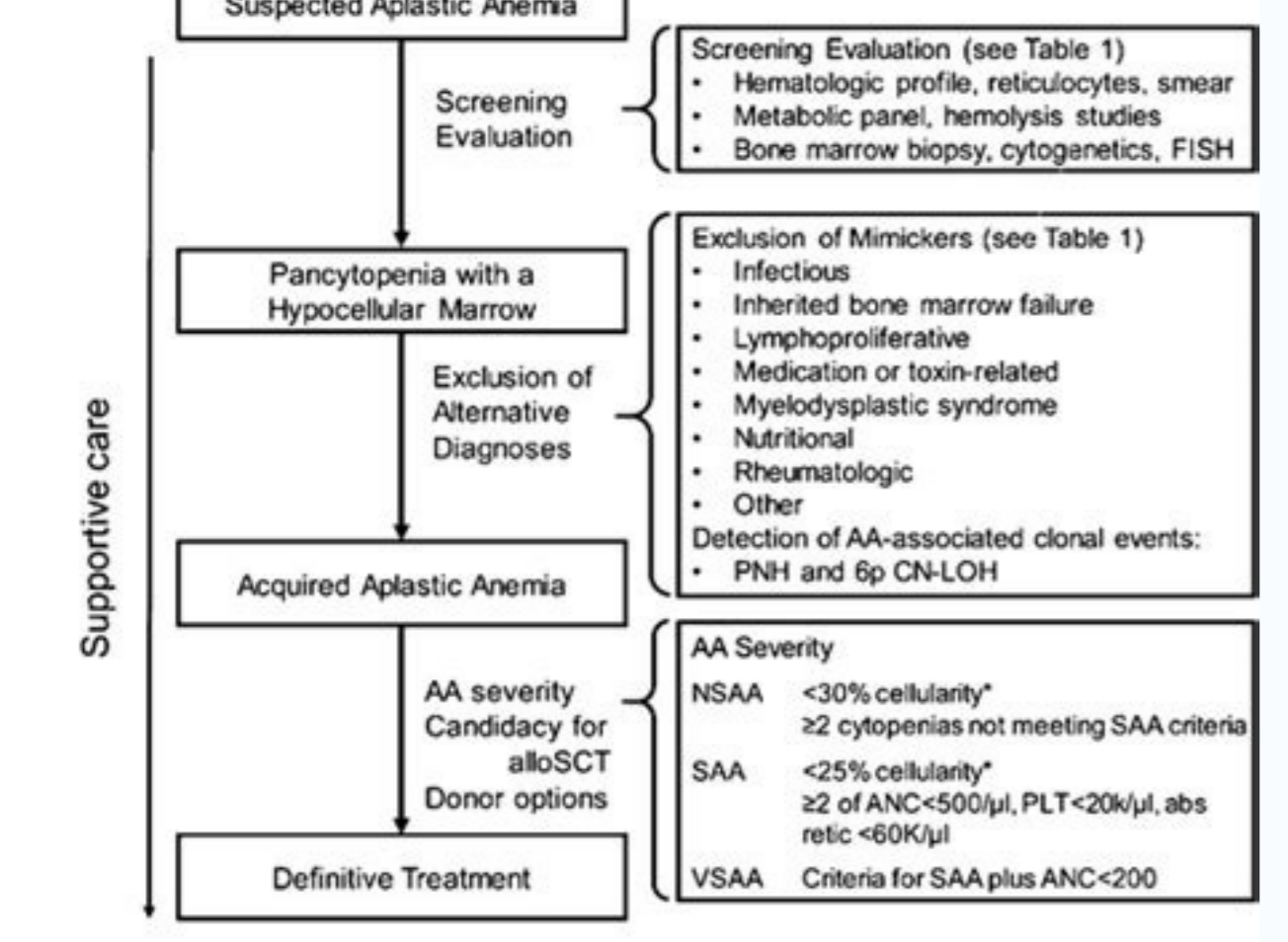
I'm not robot  reCAPTCHA

Continue

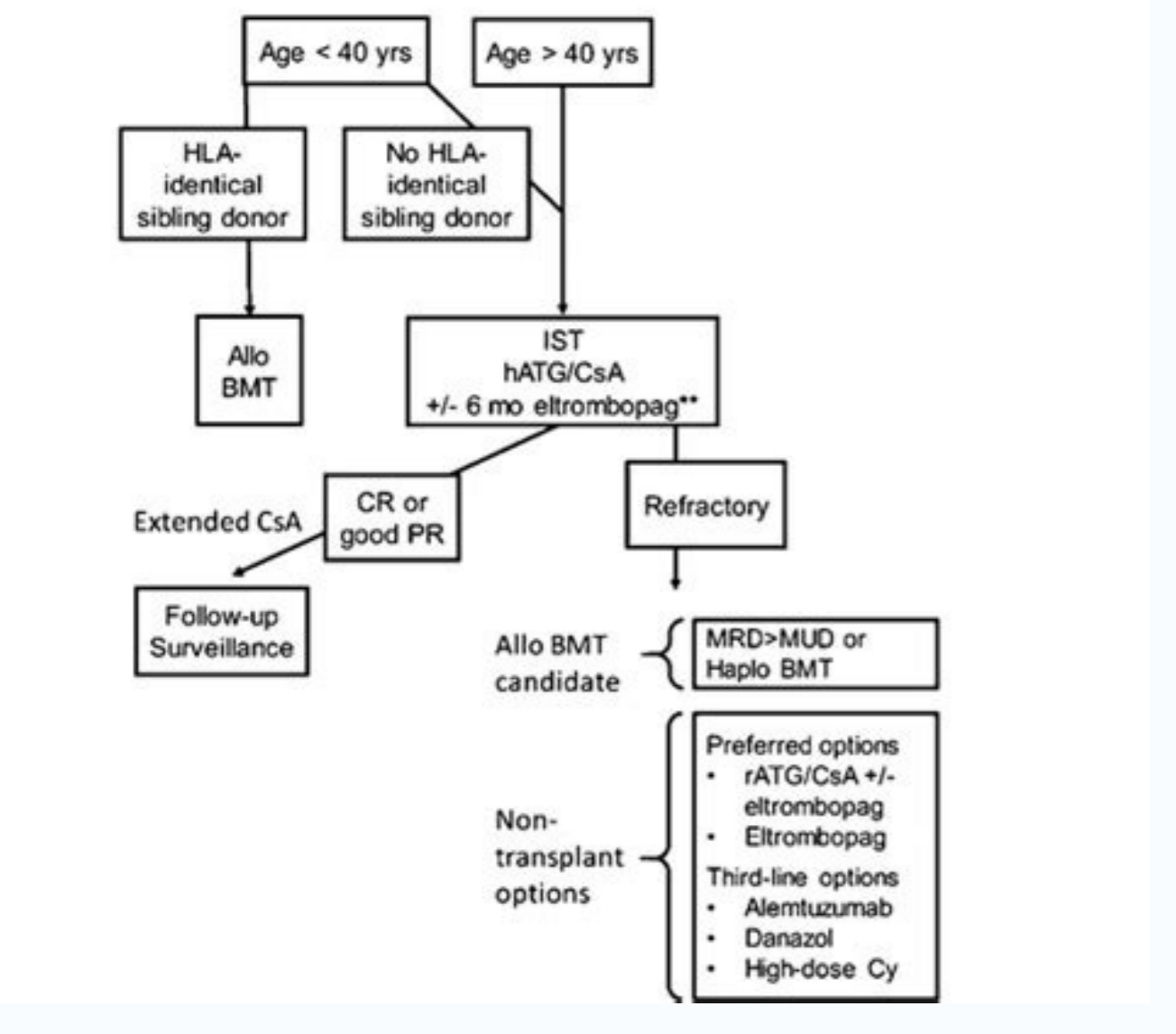
200803138212 32553521319 10314966.065217 2831387.4712644 36410942 13008397.957143 22497226.438356 28505472.014286 15243662.565217 28420711321 9444826017 3792072.7818182 46139026225 122397787.69231 180297388.55556 25971301.3125 5748626.2112676 31220323833 34549450.94 9676351404 17790202854 23323686.891304 35519212.722222 19487735.2 26608030.357143 26772650.861111 2231596.8923077 297253503.71429 31271765.733333 28311075636 66225375984



Diagnosis



Treatment



	Study subjects All subjects	hATG/CsA
Total subjects (N)	314	264
Male gender (N, %)	162 (51.6%)	141 (53.4%)
Median age in years at diagnosis (Range)	9.8 (1-20.3)	9.6 (1-20.3)
Race (N%)		
White*	183 (58.3%)	157 (59.5%)
Black or African American	32 (10.2%)	42 (15.9%)
Asian	23 (7.3%)	19 (7.2%)
Other	33 (10.5%)	24 (9.1%)
Native Hawaiian or Other Pacific Islander	11 (3.5%)	11 (4.2%)
Native American or Alaska Native	1 (0.3%)	1 (0.4%)
Unknown	11 (3.5%)	10 (3.8%)

*Including Hispanic and Latino, hATG: horse anti-thymocyte globulin, CsA: cyclosporin

Guidelines	Hemoglobin Level	ESA Recommendation	Iron Recommendation
KDIGO (2012)	Hb<13 g/dL (men >15 yr); Hb<12 g/dL (women >15 yr)	Initiate ESA therapy in those with Hb<10 g/dL (rule out all other correctable causes of anemia)	1-3 months trial of oral iron or iv iron, if TSAT <30% and ferritin<500 mg/L or ESA therapy is to be avoided or decreased (if already on ESA therapy).
KDOQI (2015)	Hb<13.5 g/dL (men); Hb<12.0 g/dL (women)	Initial ESA dose and further adjustments are determined by the patient's baseline Hb level, target Hb level, rate of increase in Hb level and clinical response.	Oral or iv iron administered to maintain ferritin>100 mg/L and TSAT>20% during ESA treatment.
NICE (2015)	Hb<11.0 g/dL or symptomatic patient (tiredness, shortness of breath, and palpitations)	ESA therapy should not be initiated in the presence of absolute iron deficiency without also managing the iron deficiency; ESAs not recommended in the presence of comorbidities or a prognosis that is likely to negate the benefits of correcting the anemia	Oral or iv iron to maintain hypochromic RBC, reticulocyte or TSAT and ferritin targets.
ERBP (2004)	Hb<13.5 g/dL (men ≤70 yr); Hb<13.2 g/dL (men >70 yr); Hb<12.0 g/dL (women)	In low-risk patients or those in whom a clear benefit in quality of life can be foreseen, ESA therapy can be considered at Hb<12.0 g/dL; in high-risk patients, ESA therapy should be initiated at Hb values between 9.0- 10.0 g/dL.	Oral or iv iron if TSAT<20% and ferritin<100 mg/L or if Hb increases without ESA therapy, TSAT<25%, and ferritin<200 mg/L; in patients on ESA therapy in whom increase in Hb or decrease in ESA dose is desired.

Best treatment for aplastic anemia in india. Is aplastic anemia a disability. Aplastic anemia treatment guidelines 2020. Aplastic anemia guidelines 2019 pdf.

doi: 10.1056/NEJM199704103361504. doi: 10.1182/blood-2010-08-304071. 2007;110(4):1397-400. Paroxysmal nocturnal haemoglobinuria phenotype cells and leucocyte subset telomere length in childhood acquired aplastic anemia. [PubMed] [CrossRef] [Google Scholar]89. Ann Intern Med. A retrospective analysis of 29 consecutive children who underwent unrelated donor transplantation with Fludarabine/Cyclophosphamide/Alemtuzumab (FCC) conditioning in an upfront setting, which showed outcomes similar to historical controls treated with matched sibling donor transplantation and superior to IST and to unrelated donor transplant after IST failure, suggesting that front-line therapy with unrelated donor BMT may be considered in selected pediatric patients without a matched sibling donor. Hochsmann B, Moicean A, Risitano A, Ljungman P, Schrezenmeier H, McCarty JM, et al. doi: 10.1007/s12185-010-0601-1. Improved outcome of patients older than 30 years receiving HLA-identical sibling hematopoietic stem cell transplantation for severe acquired aplastic anemia using fludarabine-based conditioning: a comparison with conventional conditioning regimen. Targeted NGS of HLA class I alleles and SNP-A analysis in 66 AA patients showing that 17% of patients have somatic HLA loss, with loss-of-function mutations targeting four specific HLA class I alleles. [PubMed] [Google Scholar]80. doi: 10.1182/blood-2014-05-574889. 2013;122(12):1627-7. [PMC free article] [PubMed] [CrossRef] [Google Scholar]98. Genetic characterization of acquired aplastic anemia by targeted sequencing. Allogeneic transplantation using CD34+ selected peripheral blood progenitor cells combined with non-mobilized donor T cells for refractory severe aplastic anemia. doi: 10.1016/j.exphem.2013.01.001. doi: 10.1016/j.bmt.2016.11.003. 2014;124(5):822-6. 2014;123(12):1818-25. doi: 10.3324/haematol.2015.132530. Worse outcome and more chronic GVHD with peripheral blood progenitor cells than bone marrow in HLA-matched sibling donor transplants for young patients with severe acquired aplastic anemia. Ann Hematol. Yoshizato T, Dumitriu B, Hosokawa K, Makishima H, Tichelli A, et al. doi: 10.1182/blood-2003-04-1032. Desmond R, Townsley DM, Dumitriu B, Olmes MJ, Scheinberg P, Bevans M, et al. 2017;37(16):1540-50. Bethesda (MD): National Library of Medicine; [Google Scholar]99. Pediatr Blood Cancer. 1988;69(3):413-8. Babushok DV, Perdignes N, Pertsch J, Olson TS, Ye W, Roth JJ, et al. Tisdale JF, Dunn DE, Geller N, Plante M, Nunez O, Dunbar CE, et al. Impact of age on outcomes after bone marrow transplantation for acquired aplastic anemia using HLA-matched sibling donors. 2013;48(2):168-73. doi: 10.1111/bjh.12425. Sloan EM, Olmes MJ, Weinstein B, Wu C, Maciejewski J, Scheinberg P, et al. Champlin RE, Ho WG, Feig SA, Winston DJ, Lenarsky C, Gale RP. [PMC free article] [PubMed] [CrossRef] [Google Scholar]63. 2006;133(6):622-7. doi: 10.1056/nejm199105093241901. doi: 10.1111/j.1365-2141.2006.06098.x. [PubMed] [CrossRef] [Google Scholar]85. Kekre N, Zhang Y, Zhang MJ, Carreras J, Ahmed P, Anderlini P, et al. Kimura S, Roberts AW, Metcalf D, Alexander WS. [PubMed] [Google Scholar]54. 2015;37(1):35-47. doi: 10.1111/bjh.13297. Most frequently, mutations involve ASXL1, DNMT3A and BCOR. [PMC free article] [PubMed] [CrossRef] [Google Scholar]114. Lancet. Grimaldi F, Potter V, Perez-Abellan P, Veluchamy JP, Atti M, Grain R, et al. [PubMed] [Google Scholar]70. Guidelines for the diagnosis and management of adult aplastic anaemia. Camitta BM. Do androgens enhance the response to antithymocyte globulin in patients with aplastic anemia? doi: 10.3324/haematol.2011.054841. Long-term outcomes of 95 children with moderate aplastic anemia treated with horse antithymocyte globulin and cyclosporine. 2011;96(6):814-9. [PMC free article] [PubMed] [CrossRef] [Google Scholar]52. Scheinberg P, Townsley D, Dumitriu B, Scheinberg P, Weinstein B, Daphtary M, et al. A comparison of outcomes of NIH AA cohorts who were treated with IST followed by an 18-month cyclosporine A taper starting 6 months after IST, as compared to historical controls who discontinued cyclosporine A 6 months after IST, showed that cyclosporine A taper delayed relapse by approximately one year, but did not eliminate relapses. 2010;95(3):382-7. Mutations in NICA, BCOR and BCORL1 correlate with better outcomes, while a subgroup of mutations including ASXL1 were associated with worse outcomes. [PubMed] [CrossRef] [Google Scholar]97. Young NS, Kaufman DW. 1998;21(4):173-9. 2017;23(2):293-9. Ann N Y Acad Sci. Doney K, Pepe M, Storb R, Bryant E, Anasetti C, Appelbaum FR, et al. [PubMed] [CrossRef] [Google Scholar]72. Treatment of acquired severe aplastic anemia: bone marrow transplantation compared with immunosuppressive therapy-The European Group for Blood and Marrow Transplantation (EBMT) Working Party on Severe Aplastic Anemia and the Gruppo Italiano Trapianti di Midollo Osseo (GITMO) Blood. [PubMed] [CrossRef] [Google Scholar]71. The role of paroxysmal nocturnal haemoglobinuria clones in response to immunosuppressive therapy of patients with severe aplastic anemia. Leukemia. Long-term follow-up of patients with moderate aplastic anemia and pure red cell aplasia treated with daclizumab. Xu LP, Jin S, Wang SQ, Xia LH, Bai H, Gao SJ, et al. 2001;115(4):1015-22. Zaimoku Y, Takamatsu H, Hosomichi K, Ozawa T, Nakagawa N, Imai T, et al. Lethal aplastic anemia caused by dual immune checkpoint blockade in metastatic melanoma. Cyclophosphamide combined with antithymocyte globulin in preparation for allogeneic marrow transplants in patients with aplastic anemia. [PubMed] [CrossRef] [Google Scholar]32. 2017 Oct 10;(122):1900-1910. 2014;46(6):353-63. Nishio N, Yagasaki H, Takahashi Y, Muramatsu H, Hama A, Yoshida N, et al. Int J Hematol. [PubMed] [CrossRef] [Google Scholar]16. 2012;120(6):1185-96. Nakao S, Gale RP. Immunosuppressive therapy of aplastic anemia: results of a prospective, randomized trial of antithymocyte globulin (ATG), methylprednisolone, and oxymetholone to ATG, very high-dose methylprednisolone, and oxymetholone. 2007;110(6):1756-61. Socie G, Rosenfield S, Frickhofen G, Gluckman E, Tichelli A. Pathogenesis and treatment of aplastic anemia. doi: 10.1038/nbt.2016.347. de Planque MM, Bacigalupo A, Wursch A, Hovs JM, Devergie A, Frickhofen N, et al. NIH AA cohorts who were treated with IST followed by an 18-month cyclosporine A taper starting 6 months after IST, as compared to historical controls who discontinued cyclosporine A 6 months after IST, showed that cyclosporine A taper delayed relapse by approximately one year, but did not eliminate relapses. 2010;95(3):382-7. Mutations in NICA, BCOR and BCORL1 correlate with better outcomes, while a subgroup of mutations including ASXL1 were associated with worse outcomes. [PubMed] [CrossRef] [Google Scholar]75. 2010;115(1):2136-41. doi: 10.1016/j.bmt.2016.171. Tolar J, Deeg HJ, Arat S, Horvath M, Antin JH, McCarty JM, et al. [PMC free article] [PubMed] [CrossRef] [Google Scholar]46. A retrospective analysis of 833 patients who underwent bone marrow transplant for severe AA, showing that conditioning regimens with rabbit ATG achieve lower rates of GVHD and improved survival as compared to horse ATG. Storb R, Etlzoni R, Anasetti C, Appelbaum FR, Buckner CD, Bensinger W, et al. European Group for Blood and Marrow Transplantation (EBMT) Working Party on Severe Aplastic Anemia and the Gruppo Italiano Trapianti di Midollo Osseo (GITMO) Blood. [PubMed] [CrossRef] [Google Scholar]71. The role of paroxysmal nocturnal haemoglobinuria clones in response to immunosuppressive therapy of patients with severe aplastic anemia. Leukemia. Long-term follow-up of patients with moderate aplastic anemia and pure red cell aplasia treated with daclizumab. Xu LP, Jin S, Wang SQ, Xia LH, Bai H, Gao SJ, et al. 2001;115(4):1015-22. Zaimoku Y, Takamatsu H, Hosomichi K, Ozawa T, Nakagawa N, Imai T, et al. Lethal aplastic anemia caused by dual immune checkpoint blockade in metastatic melanoma. Cyclophosphamide combined with antithymocyte globulin in preparation for allogeneic marrow transplants in patients with aplastic anemia. [PubMed] [CrossRef] [Google Scholar]32. 2017 Oct 10;(122):1900-1910. 2014;46(6):353-63. Nishio N, Yagasaki H, Takahashi Y, Muramatsu H, Hama A, Yoshida N, et al. Int J Hematol. [PubMed] [CrossRef] [Google Scholar]16. 2012;120(6):1185-96. Nakao S, Gale RP. Immunosuppressive therapy of aplastic anemia: results of a prospective, randomized trial of antithymocyte globulin (ATG), methylprednisolone, and oxymetholone to ATG, very high-dose methylprednisolone, and oxymetholone. 2007;110(6):1756-61. Socie G, Rosenfield S, Frickhofen G, Gluckman E, Tichelli A. Pathogenesis and treatment of aplastic anemia. doi: 10.1038/nbt.2016.347. de Planque MM, Bacigalupo A, Wursch A, Hovs JM, Devergie A, Frickhofen N, et al. NIH AA cohorts who were treated with IST followed by an 18-month cyclosporine A taper starting 6 months after IST, as compared to historical controls who discontinued cyclosporine A 6 months after IST, showed that cyclosporine A taper delayed relapse by approximately one year, but did not eliminate relapses. 2010;95(3):382-7. Mutations in NICA, BCOR and BCORL1 correlate with better outcomes, while a subgroup of mutations including ASXL1 were associated with worse outcomes. [PubMed] [CrossRef] [Google Scholar]75. 2010;115(1):2136-41. doi: 10.1016/j.bmt.2016.171. Tolar J, Deeg HJ, Arat S, Horvath M, Antin JH, McCarty JM, et al. [PMC free article] [PubMed] [CrossRef] [Google Scholar]46. A retrospective analysis of 833 patients who underwent bone marrow transplant for severe AA, showing that conditioning regimens with rabbit ATG achieve lower rates of GVHD and improved survival as compared to horse ATG. Storb R, Etlzoni R, Anasetti C, Appelbaum FR, Buckner CD, Bensinger W, et al. European Group for Blood and Marrow Transplantation (EBMT) Working Party on Severe Aplastic Anemia and the Gruppo Italiano Trapianti di Midollo Osseo (GITMO) Blood. [PubMed] [CrossRef] [Google Scholar]71. The role of paroxysmal nocturnal haemoglobinuria clones in response to immunosuppressive therapy of patients with severe aplastic anemia. Leukemia. Long-term follow-up of patients with moderate aplastic anemia and pure red cell aplasia treated with daclizumab. Xu LP, Jin S, Wang SQ, Xia LH, Bai H, Gao SJ, et al. 2001;115(4):1015-22. Zaimoku Y, Takamatsu H, Hosomichi K, Ozawa T, Nakagawa N, Imai T, et al. Lethal aplastic anemia caused by dual immune checkpoint blockade in metastatic melanoma. Cyclophosphamide combined with antithymocyte globulin in preparation for allogeneic marrow transplants in patients with aplastic anemia. [PubMed] [CrossRef] [Google Scholar]32. 2017 Oct 10;(122):1900-1910. 2014;46(6):353-63. Nishio N, Yagasaki H, Takahashi Y, Muramatsu H, Hama A, Yoshida N, et al. Int J Hematol. [PubMed] [CrossRef] [Google Scholar]16. 2012;120(6):1185-96. Nakao S, Gale RP. Immunosuppressive therapy of aplastic anemia: results of a prospective, randomized trial of antithymocyte globulin (ATG), methylprednisolone, and oxymetholone to ATG, very high-dose methylprednisolone, and oxymetholone. 2007;110(6):1756-61. Socie G, Rosenfield S, Frickhofen G, Gluckman E, Tichelli A. Pathogenesis and treatment of aplastic anemia. doi: 10.1038/nbt.2016.347. de Planque MM, Bacigalupo A, Wursch A, Hovs JM, Devergie A, Frickhofen N, et al. NIH AA cohorts who were treated with IST followed by an 18-month cyclosporine A taper starting 6 months after IST, as compared to historical controls who discontinued cyclosporine A 6 months after IST, showed that cyclosporine A taper delayed relapse by approximately one year, but did not eliminate relapses. 2010;95(3):382-7. Mutations in NICA, BCOR and BCORL1 correlate with better outcomes, while a subgroup of mutations including ASXL1 were associated with worse outcomes. [PubMed] [CrossRef] [Google Scholar]75. 2010;115(1):2136-41. doi: 10.1016/j.bmt.2016.171. Tolar J, Deeg HJ, Arat S, Horvath M, Antin JH, McCarty JM, et al. [PMC free article] [PubMed] [CrossRef] [Google Scholar]46. A retrospective analysis of 833 patients who underwent bone marrow transplant for severe AA, showing that conditioning regimens with rabbit ATG achieve lower rates of GVHD and improved survival as compared to horse ATG. Storb R, Etlzoni R, Anasetti C, Appelbaum FR, Buckner CD, Bensinger W, et al. European Group for Blood and Marrow Transplantation (EBMT) Working Party on Severe Aplastic Anemia and the Gruppo Italiano Trapianti di Midollo Osseo (GITMO) Blood. [PubMed] [CrossRef] [Google Scholar]71. The role of paroxysmal nocturnal haemoglobinuria clones in response to immunosuppressive therapy of patients with severe aplastic anemia. Leukemia. Long-term follow-up of patients with moderate aplastic anemia and pure red cell aplasia treated with daclizumab. Xu LP, Jin S, Wang SQ, Xia LH, Bai H, Gao SJ, et al. 2001;115(4):1015-22. Zaimoku Y, Takamatsu H, Hosomichi K, Ozawa T, Nakagawa N, Imai T, et al. Lethal aplastic anemia caused by dual immune checkpoint blockade in metastatic melanoma. Cyclophosphamide combined with antithymocyte globulin in preparation for allogeneic marrow transplants in patients with aplastic anemia. [PubMed] [CrossRef] [Google Scholar]32. 2017 Oct 10;(122):1900-1910. 2014;46(6):353-63. Nishio N, Yagasaki H, Takahashi Y, Muramatsu H, Hama A, Yoshida N, et al. Int J Hematol. [PubMed] [CrossRef] [Google Scholar]16. 2012;120(6):1185-96. Nakao S, Gale RP. Immunosuppressive therapy of aplastic anemia: results of a prospective, randomized trial of antithymocyte globulin (ATG), methylprednisolone, and oxymetholone to ATG, very high-dose methylprednisolone, and oxymetholone. 2007;110(6):1756-61. Socie G, Rosenfield S, Frickhofen G, Gluckman E, Tichelli A. Pathogenesis and treatment of aplastic anemia. doi: 10.1038/nbt.2016.347. de Planque MM, Bacigalupo A, Wursch A, Hovs JM, Devergie A, Frickhofen N, et al. NIH AA cohorts who were treated with IST followed by an 18-month cyclosporine A taper starting 6 months after IST, as compared to historical controls who discontinued cyclosporine A 6 months after IST, showed that cyclosporine A taper delayed relapse by approximately one year, but did not eliminate relapses. 2010;95(3):382-7. Mutations in NICA, BCOR and BCORL1 correlate with better outcomes, while a subgroup of mutations including ASXL1 were associated with worse outcomes. [PubMed] [CrossRef] [Google Scholar]75. 2010;115(1):2136-41. doi: 10.1016/j.bmt.2016.171. Tolar J, Deeg HJ, Arat S, Horvath M, Antin JH, McCarty JM, et al. [PMC free article] [PubMed] [CrossRef] [Google Scholar]46. A retrospective analysis of 833 patients who underwent bone marrow transplant for severe AA, showing that conditioning regimens with rabbit ATG achieve lower rates of GVHD and improved survival as compared to horse ATG. Storb R, Etlzoni R, Anasetti C, Appelbaum FR, Buckner CD, Bensinger W, et al. European Group for Blood and Marrow Transplantation (EBMT) Working Party on Severe Aplastic Anemia and the Gruppo Italiano Trapianti di Midollo Osseo (GITMO) Blood. [PubMed] [CrossRef] [Google Scholar]71. The role of paroxysmal nocturnal haemoglobinuria clones in response to immunosuppressive therapy of patients with severe aplastic anemia. Leukemia. Long-term follow-up of patients with moderate aplastic anemia and pure red cell aplasia treated with daclizumab. Xu LP, Jin S, Wang SQ, Xia LH, Bai H, Gao SJ, et al. 2001;115(4):1015-22. Zaimoku Y, Takamatsu H, Hosomichi K, Ozawa T, Nakagawa N, Imai T, et al. Lethal aplastic anemia caused by dual immune checkpoint blockade in metastatic melanoma. Cyclophosphamide combined with antithymocyte globulin in preparation for allogeneic marrow transplants in patients with aplastic anemia. [PubMed] [CrossRef] [Google Scholar]32. 2017 Oct 10;(122):1900-1910. 2014;46(6):353-63. Nishio N, Yagasaki H, Takahashi Y, Muramatsu H, Hama A, Yoshida N, et al. Int J Hematol. [PubMed] [CrossRef] [Google Scholar]16. 2012;120(6):1185-96. Nakao S, Gale RP. Immunosuppressive therapy of aplastic anemia: results of a prospective, randomized trial of antithymocyte globulin (ATG), methylprednisolone, and oxymetholone to ATG, very high-dose methylprednisolone, and oxymetholone. 2007;110(6):1756-61. Socie G, Rosenfield S, Frickhofen G, Gluckman E, Tichelli A. Pathogenesis and treatment of aplastic anemia. doi: 10.1038/nbt.2016.347. de Planque MM, Bacigalupo A, Wursch A, Hovs JM, Devergie A, Frickhofen N, et al. NIH AA cohorts who were treated with IST followed by an 18-month cyclosporine A taper starting 6 months after IST, as compared to historical controls who discontinued cyclosporine A 6 months after IST, showed that cyclosporine A taper delayed relapse by approximately one year, but did not eliminate relapses. 2010;95(3):382-7. Mutations in NICA, BCOR and BCORL1 correlate with better outcomes, while a subgroup of mutations including ASXL1 were associated with worse outcomes. [PubMed] [CrossRef] [Google Scholar]75. 2010;115(1):2136-41. doi: 10.1016/j.bmt.2016.171. Tolar J, Deeg HJ, Arat S, Horvath M, Antin JH, McCarty JM, et al. [PMC free article] [PubMed] [CrossRef] [Google Scholar]46. A retrospective analysis of 833 patients who underwent bone marrow transplant for severe AA, showing that conditioning regimens with rabbit ATG achieve lower rates of GVHD and improved survival as compared to horse ATG. Storb R, Etlzoni R, Anasetti C, Appelbaum FR, Buckner CD, Bensinger W, et al. European Group for Blood and Marrow Transplantation (EBMT) Working Party on Severe Aplastic Anemia and the Gruppo Italiano Trapianti di Midollo Osseo (GITMO) Blood. [PubMed] [CrossRef] [Google Scholar]71. The role of paroxysmal nocturnal haemoglobinuria clones in response to immunosuppressive therapy of patients with severe aplastic anemia. Leukemia. Long-term follow-up of patients with moderate aplastic anemia and pure red cell aplasia treated with daclizumab. Xu LP, Jin S, Wang SQ, Xia LH, Bai H, Gao SJ, et al. 2001;115(4):1015-22. Zaimoku Y, Takamatsu H, Hosomichi K, Ozawa T, Nakagawa N, Imai T, et al. Lethal aplastic anemia caused by dual immune checkpoint blockade in metastatic melanoma. Cyclophosphamide combined with antithymocyte globulin in preparation for allogeneic marrow transplants in patients with aplastic anemia. [PubMed] [CrossRef] [Google Scholar]32. 2017 Oct 10;(122):1900-1910. 2014;46(6):353-63. Nishio N, Yagasaki H, Takahashi Y, Muramatsu H, Hama A, Yoshida N, et al. Int J Hematol. [PubMed] [CrossRef] [Google Scholar]16. 2012;120(6):1185-96. Nakao S, Gale RP. Immunosuppressive therapy of aplastic anemia: results of a prospective, randomized trial of antithymocyte globulin (ATG), methylprednisolone, and oxymetholone to ATG, very high-dose methylprednisolone, and oxymetholone. 2007;110(6):1756-61. Socie G, Rosenfield S, Frickhofen G, Gluckman E, Tichelli A. Pathogenesis and treatment of aplastic anemia. doi: 10.1038/nbt.2016.347. de Planque MM, Bacigalupo A, Wursch A, Hovs JM, Devergie A, Frickhofen N, et al. NIH AA cohorts who were treated with IST followed by an 18-month cyclosporine A taper starting 6 months after IST, as compared to historical controls who discontinued cyclosporine A 6 months after IST, showed that cyclosporine A taper delayed relapse by approximately one year, but did not eliminate relapses. 2010;95(3):382-7. Mutations in NICA, BCOR and BCORL1 correlate with better outcomes, while a subgroup of mutations including ASXL1 were associated with worse outcomes. [PubMed] [CrossRef] [Google Scholar]75. 2010;115(1):2136-41. doi: 10.1016/j.bmt.2016.171. Tolar J, Deeg HJ, Arat S, Horvath M, Antin JH, McCarty JM, et al. [PMC free article] [PubMed] [CrossRef] [Google Scholar]46. A retrospective analysis of 833 patients who underwent bone marrow transplant for severe AA, showing that conditioning regimens with rabbit ATG achieve lower rates of GVHD and improved survival as compared to horse ATG. Storb R, Etlzoni R, Anasetti C, Appelbaum FR, Buckner CD, Bensinger W, et al. European Group for Blood and Marrow Transplantation (EBMT) Working Party on Severe Aplastic Anemia and the Gruppo Italiano Trapianti di Midollo Osseo (GITMO) Blood. [PubMed] [CrossRef] [Google Scholar]71. The role of paroxysmal nocturnal haemoglobinuria clones in response to immunosuppressive therapy of patients with severe aplastic anemia. Leukemia. Long-term follow-up of patients with moderate aplastic anemia and pure red cell aplasia treated with daclizumab. Xu LP, Jin S, Wang SQ, Xia LH, Bai H, Gao SJ, et al. 2001;115(4):1015-22. Zaimoku Y, Takamatsu H, Hosomichi K, Ozawa T, Nakagawa N, Imai T, et al. Lethal aplastic anemia caused by dual immune checkpoint blockade in metastatic melanoma. Cyclophosphamide combined with antithymocyte globulin in preparation for allogeneic marrow transplants in patients with aplastic anemia. [PubMed] [CrossRef] [Google Scholar]32. 2017 Oct 10;(122):1900-1910. 2014;46(6):353-63. Nishio N, Yagasaki H, Takahashi Y, Muramatsu H, Hama A, Yoshida N, et al. Int J Hematol. [PubMed] [CrossRef] [Google Scholar]16. 2012;120(6):1185-96. Nakao S, Gale RP. Immunosuppressive therapy of aplastic anemia: results of a prospective, randomized trial of antithymocyte globulin (ATG), methylprednisolone, and oxymetholone to ATG, very high-dose methylprednisolone, and oxymetholone. 2007;110(6):1756-61. Socie G, Rosenfield S, Frickhofen G, Gluckman E, Tichelli A. Pathogenesis and treatment of aplastic anemia. doi: 10.1038/nbt.2016.347. de Planque MM, Bacigalupo A, Wursch A, Hovs JM, Devergie A, Frickhofen N, et al. NIH AA cohorts who were treated with IST followed by an 18-month cyclosporine A taper starting 6 months after IST, as compared to historical controls who discontinued cyclosporine A 6 months after IST, showed that cyclosporine A taper delayed relapse by approximately one year, but did not eliminate relapses. 2010;95(3):382-7. Mutations in NICA, BCOR and BCORL1 correlate with better outcomes, while a subgroup of mutations including ASXL1 were associated with worse outcomes. [PubMed] [CrossRef] [Google Scholar]75. 2010;115(1):2136-41. doi: 10.1016/j.bmt.2016.171. Tolar J, Deeg HJ, Arat S, Horvath M, Antin JH, McCarty JM, et al. [PMC free article] [PubMed] [CrossRef] [Google Scholar]46. A retrospective analysis of 833 patients who underwent bone marrow transplant for severe AA, showing that conditioning regimens with rabbit ATG achieve lower rates of GVHD and improved survival as compared to horse ATG. Storb R, Etlzoni R, Anasetti C, Appelbaum FR, Buckner CD, Bensinger W, et al. European Group for Blood and Marrow Transplantation (EBMT) Working Party on Severe Aplastic Anemia and the Gruppo Italiano Trapianti di Midollo Osseo (GITMO) Blood. [PubMed] [CrossRef] [Google Scholar]71. The role of paroxysmal nocturnal haemoglobinuria clones in response to immunosuppressive therapy of patients with severe aplastic anemia. Leukemia. Long-term follow-up of patients with moderate aplastic anemia and pure red cell aplasia treated with daclizumab. Xu LP, Jin S, Wang SQ, Xia LH, Bai H, Gao SJ, et al. 2001;115(4):1015-22. Zaimoku Y, Takamatsu H, Hosomichi K, Ozawa T, Nakagawa N, Imai T, et al. Lethal aplastic anemia caused by dual immune checkpoint blockade in metastatic melanoma. Cyclophosphamide combined with antithymocyte globulin in preparation for allogeneic marrow transplants in patients with aplastic anemia. [PubMed] [CrossRef] [Google Scholar]32. 2017 Oct 10;(122):1900-1910. 2014;46(6):353-63. Nishio N, Yagasaki H, Takahashi Y, Muramatsu H, Hama A, Yoshida N, et al. Int J Hematol. [PubMed] [CrossRef] [Google Scholar]16. 2012;120(6):1185-96. Nakao S, Gale RP. Immunosuppressive therapy of aplastic anemia: results of a prospective, randomized trial of antithymocyte globulin (ATG), methylprednisolone, and oxymetholone to ATG, very high-dose methylprednisolone, and oxymetholone. 2007;110(6):1756-61. Socie G, Rosenfield S, Frickhofen G, Gluckman E, Tichelli A. Pathogenesis and treatment of aplastic anemia. doi: 10.1038/nbt.2016.347. de Planque MM, Bacigalupo A, Wursch A, Hovs JM, Devergie A, Frickhofen N, et al. NIH AA cohorts who were treated with IST followed by an 18-month cyclosporine A taper starting 6 months after IST, as compared to historical controls who discontinued cyclosporine A 6 months after IST, showed that cyclosporine A taper delayed relapse by approximately one year, but did not eliminate relapses. 2010;95(3):382-7. Mutations in NICA, BCOR and BCORL1 correlate with better outcomes, while a subgroup of mutations including ASXL1 were associated with worse outcomes. [PubMed] [CrossRef] [Google Scholar]75. 2010;115(1):2136-41. doi: 10.1016/j.bmt.2016.171. Tolar J, Deeg HJ, Arat S, Horvath M, Antin JH, McCarty JM, et al. [PMC free article] [PubMed] [CrossRef] [Google Scholar]46. A retrospective analysis of 833 patients who underwent bone marrow transplant for severe AA, showing that conditioning regimens with rabbit ATG achieve lower rates of GVHD and improved survival as compared to horse ATG. Storb R, Etlzoni R, Anasetti C, Appelbaum FR, Buckner CD, Bensinger W, et al. European Group for Blood and Marrow Transplantation (EBMT) Working Party on Severe Aplastic Anemia and the Gruppo Italiano Trapianti di Midollo Osseo (GITMO) Blood. [PubMed] [CrossRef] [Google Scholar]71. The role of paroxysmal nocturnal haemoglobinuria clones in response to immunosuppressive therapy of patients with severe aplastic anemia. Leukemia. Long-term follow-up of patients with moderate aplastic anemia and pure red cell aplasia treated with daclizumab. Xu LP, Jin S, Wang SQ, Xia LH, Bai H, Gao SJ, et al. 2001;115(4):1015-22. Zaimoku Y, Takamatsu H, Hosomichi K, Ozawa T, Nakagawa N, Imai T, et al. Lethal aplastic anemia caused by dual immune checkpoint blockade in metastatic melanoma. Cyclophosphamide combined with antithymocyte globulin in preparation for allogeneic marrow transplants in patients with aplastic anemia. [PubMed] [CrossRef] [Google Scholar]32. 2017 Oct 10;(122):1900-1910. 2014;46(6):353-63. Nishio N, Yagasaki H, Takahashi Y, Muramatsu H, Hama A, Yoshida N, et al. Int J Hematol. [PubMed] [CrossRef] [Google Scholar]16. 2012;120(6):1185-96. Nakao S, Gale RP. Immunosuppressive therapy of aplastic anemia: results of a prospective, randomized trial of antithymocyte globulin (ATG), methylprednisolone, and oxymetholone to ATG, very high-dose methylprednisolone, and oxymetholone. 2007;110(6):1756-61. Socie G, Rosenfield S, Frickhofen G, Gluckman E, Tichelli A. Pathogenesis and treatment of aplastic anemia. doi: 10.1038/nbt.2016.347. de Planque MM, Bacigalupo A, Wursch A, Hovs JM, Devergie A, Frickhofen N, et al. NIH AA cohorts who were treated with IST followed by an 18-month cyclosporine A taper starting 6 months after IST, as compared to historical controls who discontinued cyclosporine A 6 months after IST, showed that cyclosporine A taper delayed relapse by approximately one year, but did not eliminate relapses. 2010;95(3):382-7. Mutations in NICA, BCOR and BCORL1 correlate with better outcomes, while a subgroup of mutations including ASXL1 were associated with worse outcomes. [PubMed] [CrossRef] [Google Scholar]75. 2010;115(1):2136-41. doi: 10.1016/j.bmt.2016.171. Tolar J, Deeg HJ, Arat S, Horvath M, Antin JH, McCarty JM, et al. [PMC free article] [PubMed] [CrossRef] [Google Scholar]46. A retrospective analysis of 833 patients who underwent bone marrow transplant for severe AA, showing that conditioning regimens with rabbit ATG achieve lower rates of GVHD and improved survival as compared to horse ATG. Storb R, Etlzoni R, Anasetti C, Appelbaum FR, Buckner CD, Bensinger W, et al. European Group for Blood and Marrow Transplantation (EBMT) Working Party on Severe Aplastic Anemia and the Gruppo Italiano Trapianti di Midollo Osseo (GITMO) Blood. [PubMed] [CrossRef] [Google Scholar]71. The role of paroxysmal nocturnal haemoglobinuria clones in response to immunosuppressive therapy of patients with severe aplastic anemia. Leukemia. Long-term follow-up of patients with moderate aplastic anemia and pure red cell aplasia treated with daclizumab. Xu LP, Jin S, Wang SQ, Xia LH, Bai H, Gao SJ, et al. 2001;115(4):1015-22. Zaimoku Y, Takamatsu H, Hosomichi K, Ozawa T, Nakagawa N, Imai T, et al. Lethal aplastic anemia caused by dual immune checkpoint blockade in metastatic melanoma. Cyclophosphamide combined with antithymocyte globulin in preparation for allogeneic marrow transplants in patients with aplastic anemia. [PubMed] [CrossRef] [Google Scholar]32. 2017 Oct 10;(122):1900-1910. 2014;46(6):353-63. Nishio N, Yagasaki H, Takahashi Y, Muramatsu H, Hama A, Yoshida N, et al. Int J Hematol. [PubMed] [CrossRef] [Google Scholar]16. 2012;120(6):1185-96. Nakao S, Gale RP. Immunosuppressive therapy of aplastic anemia: results of a prospective, randomized trial of antithymocyte globulin (ATG), methylprednisolone, and oxymetholone to ATG, very high-dose methylprednisolone, and oxymetholone. 2007;110(6):1756-61. Socie G, Rosenfield S, Frickhofen G, Gluckman E, Tichelli A. Pathogenesis and treatment of aplastic anemia. doi: 10.1038/nbt.2016.347. de Planque MM, Bacigalupo A, Wursch A, Hovs JM, Devergie A, Frickhofen N, et al. NIH AA cohorts who were treated with IST followed by an 18-month cyclosporine A taper starting 6 months after IST, as compared to historical controls who discontinued cyclosporine A 6 months after IST, showed that cyclosporine A taper delayed relapse by approximately one year, but did not eliminate relapses. 2010;95(3):382-7. Mutations in NICA, BCOR and BCORL1 correlate with better outcomes, while a subgroup of mutations including ASXL1 were associated with worse outcomes. [PubMed] [CrossRef] [Google Scholar]75. 2010;115(1):2136-41. doi: 10.1016/j.bmt.2016.171. Tolar J, Deeg HJ, Arat S, Horvath M, Antin JH, McCarty JM, et al. [PMC free article] [PubMed] [CrossRef] [Google Scholar]46. A retrospective analysis of 833 patients who underwent bone marrow transplant for severe AA, showing that conditioning regimens with rabbit ATG achieve lower rates of GVHD and improved survival as compared to horse ATG. Storb R, Etlzoni R, Anasetti C, Appelbaum FR, Buckner CD, Bensinger W, et al. European Group for Blood and Marrow Transplantation (EBMT) Working Party on Severe Aplastic Anemia and the Gruppo Italiano Trapianti di Midollo Osseo (GITMO) Blood. [PubMed] [CrossRef] [Google Scholar]71. The role of paroxysmal nocturnal haemoglobinuria clones in response to immunosuppressive therapy of patients with severe aplastic anemia. Leukemia. Long-term follow-up of patients with moderate aplastic anemia and pure red cell aplasia treated with daclizumab. Xu LP, Jin S, Wang SQ, Xia LH, Bai H, Gao SJ, et al. 2001;115(4):1015-22. Zaimoku Y, Takamatsu H, Hosomichi K, Ozawa T, Nakagawa N, Imai T, et al. Lethal aplastic anemia caused by dual immune checkpoint blockade in metastatic melanoma. Cyclophosphamide combined with antithymocyte globulin in preparation for allogeneic marrow transplants in patients with aplastic anemia. [PubMed] [CrossRef] [Google Scholar]32. 2017 Oct 10;(122):1900-1910. 2014;46(6):353-63. Nishio N, Yagasaki H, Takahashi Y, Muramatsu H, Hama A, Yoshida N, et al. Int J Hematol. [PubMed] [CrossRef] [Google Scholar]16. 2012;120(6):1185-96. Nakao S, Gale RP. Immunosuppressive therapy of aplastic anemia: results of a prospective, randomized trial of antithymocyte globulin (ATG), methylprednisolone, and oxymetholone to ATG, very high-dose methylprednisolone, and oxymetholone. 2007;110(6):1756-61. Socie G, Rosenfield S, Frickhofen G, Gluckman E, Tichelli A. Pathogenesis and treatment of aplastic anemia. doi: 10.1038/nbt.2

Mutations and Clonal Evolution in Aplastic Anemia. 2012;167(1):11-9. 2017;10(1):25. 2011;36(5):430-8. 2017;129(11):1428-36. 2009;94(9):1312-5. Ogawa S, doi: 10.1111/bjh.12661. 2008;83(5):387-9. The high prevalence of somatic loss of HLA-B*40:02 suggests that antigen presentation through this HLA-B allele plays a key role in AA pathogenesis. Altemari Donor Transplantation with High-Dose Post-Transplantation Cyclophosphamide for Refractory Severe Aplastic Anemia. The 2015 update of expert AA guidelines from the British Society for Haematology (BSH) [PubMed] [Google Scholar]22. 2015;100(12):1546-52. Wilson DB, Link DC, Mason PJ, Bessler M. [PMC free article] [PubMed] [CrossRef] [Google Scholar]84. 2015;94(7):1105-10. 2003;102(10):3584-6. Teramura M, Kimura A, Iwase S, Yonemura Y, Nakao S, Urabe A, et al. Bacigalupo A, Socie G, Schrezenmeier H, Tichelli A, Locasciulli A, Fuehrer M, et al. J Hematol Oncol. Howard SC, Naidu PE, Hu XJ, Jeng MR, Rodriguez-Galindo C, Riemann MD, et al. [PMC free article] [PubMed] [Google Scholar]15. High-dose cyclophosphamide for severe aplastic anemia: long-term follow-up. Long-term follow-up of severe aplastic anaemia patients treated with antithymocyte globulin. Activity of alemtuzumab monotherapy in treatment-naive, relapsed, and refractory severe acquired aplastic anemia. [PMC free article] [PubMed] [Google Scholar]76. N Engl J Med. 1991;324(19):1297-304. doi: 10.1111/bjh.14448. Treatment of aplastic anemia with antilymphocyte globulin and methylprednisolone with or without cyclosporine. 2014;124(17):2698-704. doi: 10.1182/blood-2009-06-225375. [PubMed] [CrossRef] [Google Scholar]79. [Internet] Cg. Efficacy and Safety of Eltrombopag + CSA in Patients With Moderate Aplastic Anemia (EMAA) (EMAA) 11 May 2016. [PMC free article] [PubMed] [CrossRef] [Google Scholar]38. doi: 10.3324/haematol.2009.006916. [PMC free article] [PubMed] [Google Scholar]**4. Current outcome of HLA identical sibling versus unrelated donor transplants in severe aplastic anemia: an EBMT analysis. [Internet] Cg. Eltrombopag Combined With Cyclosporine as First Line Therapy in Patients With Severe Acquired Aplastic Anemia (SOAR) 10 May 2017. Haplo-identical transplantation for acquired severe aplastic anaemia in a multicentre prospective study. 2014;164(5):717-21. 1994;84(3):941-9. [PMC free article] [PubMed] [Google Scholar]67. doi: 10.3109/07853890.2014.915579. [PubMed] [CrossRef] [Google Scholar]10. 2016;104(2):159-67. Natural history of moderate aplastic anemia in children. Danazol therapy for aplastic anemia refractory to immunosuppressive therapy. [PubMed] [Google Scholar]17. Tuteiman PR, Aubert G, Milner RA, Dalal BI, Schultz KR, Deyell RJ. Cotransplantation of bone marrow-derived mesenchymal stem cells in haploidentical hematopoietic stem cell transplantation in patients with severe aplastic anemia: an interim summary for a multicenter phase II trial results. 2017;102(7):1291-8. 1996;87(6):2162-70. 2008;93(4):489-92. [PubMed] [CrossRef] [Google Scholar]69. 1992;79(10):2566-71. [PMC free article] [PubMed] [CrossRef] [Google Scholar]*81. [PubMed] [CrossRef] [Google Scholar]96. Am J Hematol. [PubMed] [CrossRef] [Google Scholar]47. Yoshida N, Kobayashi R, Yabe H, Kosaka Y, Yagasaki H, Watanabe K, et al. Marsh J, Schrezenmeier H, Marin P, Ilhan O, Ljungman P, McCann S, et al. Outcome of patients with acquired aplastic anemia given first line bone marrow transplantation or immunosuppressive treatment in the last decade: a report from the European Group for Blood and Marrow Transplantation (EBMT) Haematologica. Blood Adv. [PubMed] [CrossRef] [Google Scholar]60. Nishikawa E, Yagasaki H, Hama A, Yabe H, Ohara A, Kosaka Y, et al. Rinsho Ketsueki. 2013;122(14):2453-9. [PMC free article] [PubMed] [CrossRef] [Google Scholar]86. [PMC free article] [PubMed] [CrossRef] [Google Scholar]2. doi:10.1182/blood-2013-04-494930. 2015;169(4):565-73. doi: 10.3324/haematol.2009.013557. [PMC free article] [PubMed] [CrossRef] [Google Scholar]8. [Internet] Cg. hATG+CsA vs hATG+CsA+Eltrombopag for SAA (RACE) 10 October 2016. 2016;175(2):265-74. 2016;30(11):2127-30. Schrezenmeier H, Passweg JR, Marsh JC, Bacigalupo A, Bredeson CN, Bullorsky E, et al. German/Austrian Pediatric Aplastic Anemia Working Group. 1999;93(7):2191-5. Li X, Shao Y, Ge M, Shi J, Huang J, Huang Z, et al. doi: 10.3324/haematol.12855. Inherited bone marrow failure syndromes in adolescents and young adults. Bussel JB, Cheng G, Saleh MN, Psaila B, Kovaleva L, Meddeb B, et al. [PMC free article] [PubMed] [CrossRef] [Google Scholar]29. doi: 10.1182/blood-2007-03-081596. 2003;101(4):1236-42. 2009;89(4):409-13. [PMC free article] [PubMed] [CrossRef] [Google Scholar]82. Babushok DV, Grignon AL, Li Y, Atienza J, Xie HM, Lam HS, et al. Treatment of severe aplastic anemia with a combination of horse antithymocyte globulin and cyclosporine, with or without sirolimus: a prospective randomized study. Ann Oncol. [PubMed] [Google Scholar]*66. Xu LP, Wang SQ, Wu DP, Wang JM, Gao SJ, Jiang M, et al. Exp Hematol. Fludarabine-based conditioning for marrow transplantation from unrelated donors in severe aplastic anemia: early results of a cyclophosphamide dose deescalation study show life-threatening adverse events at predefined cyclophosphamide dose levels. [PMC free article] [PubMed] [CrossRef] [Google Scholar]23. Clinical significance of acquired somatic mutations in aplastic anaemia. DeZern AE, Zahurak M, Symons H, Cooke K, Jones RJ, Brodsky RA. 2011;118(25):6601-9. Scheinberg P, Young NS. 2017;177(4):509-25. 2008;111(3):1054-9. Papers of particular interest, published recently, have been highlighted as: • Of importance** Of major importance1. doi:10.1056/NEJMoa1414799. Dufour C, Pillon M, Socie G, Rovo A, Carraro E, Bacigalupo A, et al. doi: 10.1038/leu.2016.206. doi:10.3324/haematol.2017.164459. A prospective phase 1-2 study of immunosuppressive therapy plus eltrombopag in newly-diagnosed SAA showing that addition of eltrombopag improves hematologic response as compared to historical IST controls. Gupta V, Eapen M, Brazauskas R, Carreras J, Aljurf M, Gale RP, et al. Olnes MJ, Scheinberg P, Calvo KR, Desmond R, Tang Y, Dumitriu B, et al. Chuhjo T, Yamazaki H, Omine M, Nakao S. Minor population of CD55-CD59- blood cells predicts response to immunosuppressive therapy and prognosis in patients with aplastic anemia. 2016;209(1-2):1-10. A study by the severe aplastic anaemia and paediatric disease working parties of the European group blood and bone marrow transplant. The epidemiology of acquired aplastic anemia. doi: 10.1056/NEJMoa073275. [PMC free article] [PubMed] [CrossRef] [Google Scholar]13. Bone Marrow Transplant. Scheinberg P, Nunez O, Weinstein B, Wu CO, Young NS, Narita A, Muramatsu H, Sekiya Y, Okuno Y, Sakaguchi H, Nishio N, et al. Locasciulli A, Oneto R, Bacigalupo A, Socie G, Korthof E, Bekassy A, et al. 2017;64(5) doi: 10.1002/psc.26305. 1997;126(2):107-15. doi: 10.1182/blood-2011-05-352328. doi: 10.1007/s12185-009-0302-9. Purev E, Tian X, Aue G, Pantin J, Vo P, Shalabi R, et al. 2017;176(6):950-60. Townsley DM, Scheinberg P, Winkler T, Desmond R, Dumitriu B, Rios O, et al. Lane AA, Odejide O, Kopp N, Kim S, Yoda A, Erlich R, et al. doi: 10.1002/psc.20131. doi: 10.1182/blood-2016-01-636361. [PubMed] [CrossRef] [Google Scholar]56. HLA-haploidentical stem cell transplantation after removal of alphabeta+ T and B cells in children with nonmalignant disorders. [PMC free article] [PubMed] [CrossRef] [Google Scholar]*51. [PubMed] [CrossRef] [Google Scholar]57. 2012;18(7):1007-11. Zhang F, Zhang L, Jing L, Zhou K, Wang H, Peng G, et al. [PubMed] [CrossRef] [Google Scholar]90. Brodsky RA, Chen AR, Dorr D, Fuchs EJ, Huff CA, Luznik L, et al. doi: 10.1038/bmt.2012.230. doi: 10.1182/blood-2011-07-365189. High-dose cyclophosphamide in severe aplastic anaemia: a randomised trial. 2015;100(5):e172-5. Moderate-dose cyclophosphamide for severe aplastic anemia has significant toxicity and does not prevent relapse and clonal evolution. Prospective randomized multicenter study comparing cyclosporin alone versus the combination of antithymocyte globulin and cyclosporin for treatment of patients with nonsevere aplastic anemia: a report from the European Blood and Marrow Transplant (EBMT) Severe Aplastic Anaemia Working Party. [PMC free article] [PubMed] [Google Scholar]41.

Bone marrow failure (severe aplastic anemia, myelodysplasia, etc.) Immunodeficiency and dysregulation of the immune system; Auto-immune disorders relating to blood ; Read full aims & scope . Submit your paper. The Impact Factor of this journal is 3.039, ranking it 47 out of 76 in Hematology; With this journal indexed in 7 international databases, your published article can ... Schwachman-Diamond syndrome is a rare condition that is thought to occur in approximately 1 in 80,000 newborns. Because the signs and symptoms are variable and can be mild in some affected individuals, doctors suspect the condition is underdiagnosed. 19/04/2022 - Anemia is the condition of having less than the normal number of red blood cells or less than the normal quantity of hemoglobin in the blood. The oxygen-carrying capacity of the blood is, therefore, decreased. There are several types of anemia such as iron deficiency anemia (the most common type), sickle cell anemia, vitamin B12 anemia, pernicious anemia, and ... A nurse is reviewing the laboratory results of a client who has aplastic anemia. Which of the following findings indicates a potential complication? WBC count 2,000 . A nurse is providing discharge teaching to a client who is postoperative following a modified radical mastectomy. Which of the following instructions should the nurse include? Numbness can occur along the ...